

Main Report

MedLEaPR - UTTAR PRADESH
CHC Khaga
Fatehpur
FORM-VI

MEDICAL LEGAL REPORT- POST MORTEM EXAMINATION REPORT

(Pending Freeze)

PMR No(Generated by Software):- M431016152500019

Date:- 21/12/2025

PMR No(Given by Doctor):- 1402

Date:- 21/12/2025

Details of Doctor/Doctors who examined the patient:			
Sr No.	Doctor's Name	Designation	Registration No of Doctor with State Council/MCI
1	Mohd Khurshid	MO	75223

Victim Details:

Name Mr. Mahendra Pratap
Relative Name(Father) Late Ramgopal
Age(Approx) 60 Years 0 Months 0 Days
Gender MALE
Marital Status MARRIED
Occupation FarmerZamindar
Present Address Bijauli
Nationality Indian
State UTTAR PRADESH
District FATEHPUR
Police Station CHANDPUR
Date & Time of receipt of Inquest papers (in hrs) 21/12/2025 02:00 PM
Date & Time of receipt of body in the mortuary (in hrs) 21/12/2025 11:30 AM
Date and Time of Commencement of Autopsy (in hrs) 21/12/2025 02:00 PM
Complete Date and Time of Autopsy (in hrs) 21/12/2025 02:30 PM

क्षेत्राधिकारी फतेहपुर
कृपया आवश्यक कार्यवाही करें।
पुलिस अधीक्षक फतेहपुर
शहंशुभांग
आठ राय-रुद्र

Police FIR/DDR/Application Detail:FIR

FIR No	Date	Under Section	State(CCTNS)	District(CCTNS)	Police Station(CCTNS)
0345	20/12/2025	106(1) 1325(a) 281, 324(4)	UTTAR PRADESH	FATEHPUR	HUSSAINGANJ

Police Accompanied : Yes

SrNo.	Name	Rank	Belt No	Police Station, District, State	Email	Phone	Signature
1	Jitendra Singh	CONSTABLE	162831261	HUSSAINGANJ, FATEHPUR, UTTAR PRADESH		7007405680	

Case: No

Marks of Identification

Sl. No.	Identification Details
1	Black mole present on left shoulder region

In case of Hospital death : No


Information Supplied by the Police and/or Hospital Record (Symptoms Observed)
As Per Information Provided by Police
yes
As Per Hospital Record
NA

General Description / Examination

Description of clothes/jewellery and other items worn on the body (Important areas be encircled on the clothing wherever possible and handed over to the police)	1. grey jacket 2. sweater brown 3. muffler brown 4. multi colour shirt 5. grey woollen inner 6. white banayn 7. red white thread
Length	170 cm
Physique	Average Built
Rigor Mortis	Yes
Rigor Mortis Remarks	present on both upper and lower extremities
Post mortem staining	present on dependent part of body
Any Other Finding	NA

External General Appearance	
State of eyes :	
Pupil(Rt)	Dilated
Pupil(Lt)	Dilated
Cornea/Conjunctiva(Rt)	Normal
Cornea/Conjunctiva(Lt)	Normal
Natural orifices(Please note presence of blood, froth etc in mouth, nose, ears (specify(Rt,Lt),anus,vagina and urethra)	NA
Any Other	NA

Injury Details: Yes


भिकित्साधिकारी
शव विच्छेदन गृह
मतेहपुर

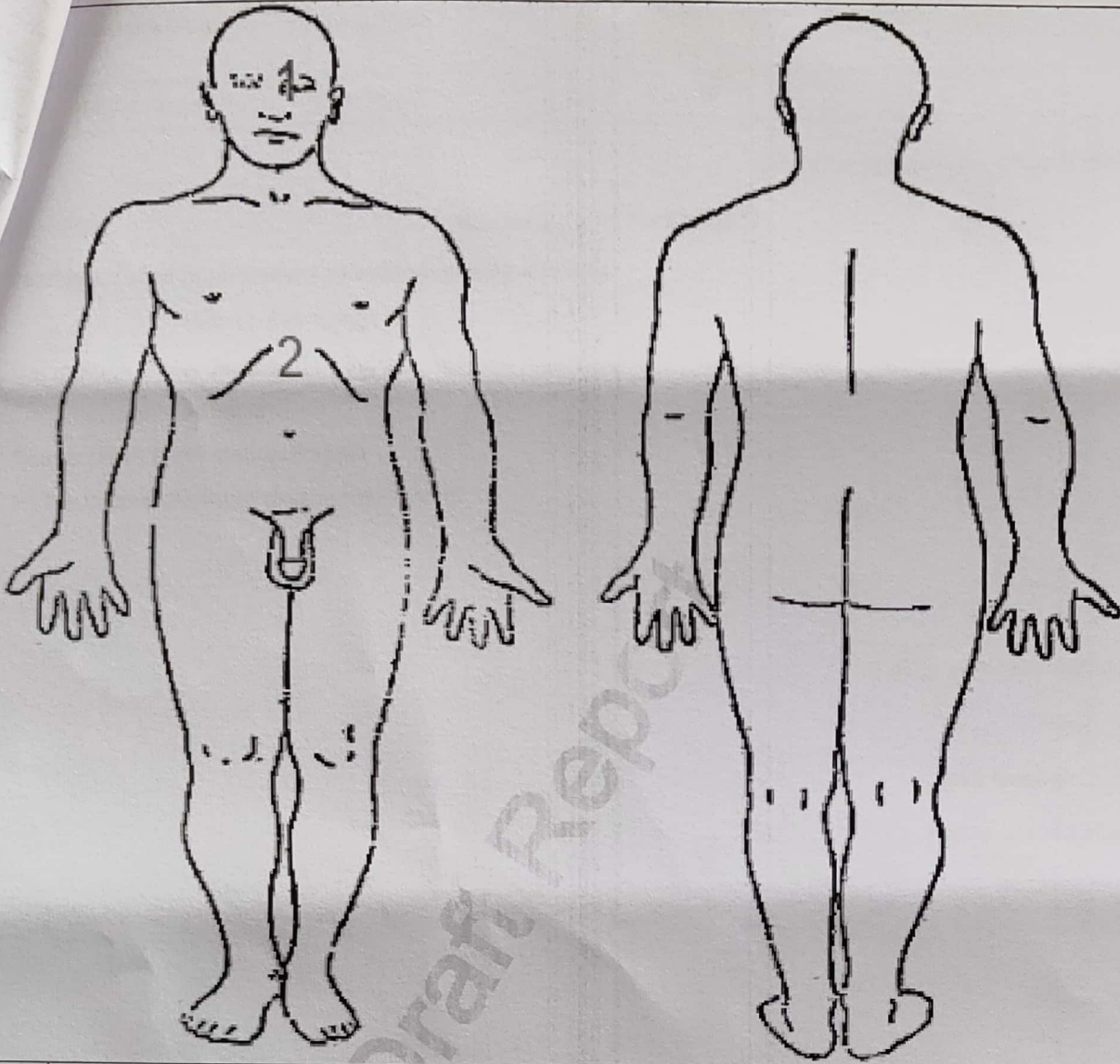
Injury Details	Injury Number	Pictorial depiction?
Crush injury present on whole head and face with underlying bone fracture and brain matter missing	1	Yes
Contusion present on whole chest and abdomen region multiple ribs fracture BL	2	Yes

S.No	Component	Remarks
1	Cranium & spinal Cord (Brain must be exposed in every case, Spinal cord need not to be examined except in case of injury to vertebral column/Spinal Cord)	
	Scalp	as noted
	Skull	multiple bone fracture
	Meninges and Vessels	missing
	Brain	missing
	Vertebrae & Spinal Cord	Not open
2	Mouth, Pharynx & Oesophagus.	as noted
3	Neck	NAD
	Condition of neck tissues Thyroid	NAD
	Hyoid bone	Intact
	Larynx & Trachea	NAD
4	Thorax	
	Chest wall,Ribs/Sternum and Cartilage	multiple ribs fracture BL
	Pleura / pleural Cavity.	about 500ml blood and clot present
	Lung(Rt)	lacerated
	Lung(Lt)	lacerated
	Pericardium	NAD
	Heart	empty
	Coronary Arteries & Large Blood Vessel	NAD
5	Abdomen	
	Peritoneum, Retroperitoneum	NAD
	Stomach and its contents	about 400ml semi digestive food material present
	Small Intestine and its content	partially filled with gases and pasty material
	Large Intestine and its content	partially filled with gases and fecal matter
	Liver and Gall Bladder	lacerated GB half full
	Spleen	lacerated
	Pancreas	NAD
	Kidney(Rt.)	lacerated
	Kidney(Lt.)	lacerated
	Urinary Bladder	empty

चिकित्साधिकारी
महानिरीक्षण गृह
नवहपुर


Muscles, bones and joints (Injury/Injuries,Diseases Deformity,Fractures,Dislocation)






sno	Injury Details	Injury Number
1	Injury No.1, Crush injury present on whole head and face with underlying bone fracture and brain matter missing	1
2	Injury No.2, Contusion present on whole chest and abdomen region multiple ribs fracture BL	2

OPINION	
Cause of Death	Shock and hemorrhage as a result of ante mortem injuries
Antemortem/Postmortem	ante mortem injuries
Probable time	
a.Between injury and death	NA
b.Between death and postmortem examination	about one day


 चिकित्साधिकारी
 मव विच्छेदन गृह
 तेहपुर

of Doctor/s who examined the patient with signature:

Doctor's Name	Designation	Registration Details	Signature
Mohd Khurshid	MO	75223	

CHC Khaga Fatehpur, UTTAR PRADESH

Handed over to the Police

Dead body after post-mortem examination duly stitched.

-With its Belongings

Belongings of the deceased : Sealed

as noted

Post Mortem Examination Report

Police Inquest Paper(s) Numbering 1 to 15

चिकित्साधिकारी
शव विच्छेदन गृह
फतेहपुर

Received

(Signature of Officer)

Officer Name :Jitendra Singh

Date 21/12/2025

Belt Number:162831261

Police Station:Husainganj

Draft Report



